ELSEVIER
SAUNDERS

Clin Lab Med 26 (2006) 67–97

CLINICS IN
LABORATORY
MEDICINE

Heavy Metal Poisoning: Clinical Presentations and Pathophysiology

Danyal Ibrahim, MD[a], Blake Froberg, MD[a], Andrea Wolf, MD[b], Daniel E. Rusyniak, MD[a,*]

[a]*Department of Emergency Medicine, Division of Medical Toxicology, Indiana University School of Medicine, 1050 Wishard Boulevard, Room 2200, Indianapolis, IN 46202, USA*

[b]*Department of Emergency Medicine, Indiana University School of Medicine, 1050 Wishard Boulevard, Room 2200, Indianapolis, IN 46202, USA*

Heavy metals are natural components of the earth's crust and as such are the oldest toxins known to humans, having been used for thousands of years. Potential exposures to heavy metals include natural sources (eg, groundwater, metal ores), industrial processes, commercial products, folk remedies, and contaminated food and herbal products. Virtually all heavy metals are toxic in sufficient quantities. Several, however, are of particular interest because of their concentrations in the environment (lead, mercury, and arsenic) or their use in criminal poisonings (arsenic and thallium). Entering our bodies by way of food, drinking water, and air, metals produce toxicity by forming complexes with cellular compounds containing sulfur, oxygen, or nitrogen. The complexes inactivate enzyme systems or modify critical protein structures leading to cellular dysfunction and death. The most commonly involved organ systems include central nervous, gastrointestinal (GI), cardiovascular, hematopoietic, renal, and peripheral nervous systems. The nature and severity of toxicity vary with the heavy metal involved, its exposure level, chemical and valance states (inorganic versus organic), mode of exposure (acute versus chronic), and the age of the individual. Children, with their developing nervous systems, are particularly vulnerable to heavy metal intoxication (especially lead) and deserve special consideration. This article presents an overview of the aforementioned heavy metals with emphasis on clinical presentation and pathophysiology.

* Corresponding author.
E-mail address: drusynia@iupui.edu (D.E. Rusyniak).

doi:10.1016/j.cll.2006.02.003

Arsenic

Clinical scenario

A 46-year-old chemical engineer presented to the emergency department with symptoms of nausea, vomiting, fatigue, extremity paresthesias, and dark-brown urine. Symptoms began within a few hours after troubleshooting newly installed equipment for wastewater treatment. The facility at which he worked manufactures silicone wafers, a process that generates wastewater containing arsenic. Over the next 24 hours, he developed hemolytic anemia, jaundice, and oliguric renal failure. His initial urine arsenic level was 1470 μg/L. The patient was treated with red blood cell (RBC) exchange transfusions, plasmapheresis, and hemodialysis, with eventual full recovery of his renal function. It was determined later that arsine gas was produced when arsenic inadvertently reacted with an acid in the electrocoagulation chamber of the equipment on which he was working.

Background

Over the centuries, arsenic has been used for various purposes. Hippocrates prescribed a paste of arsenic sulfide to treat skin conditions [1]. Arsenic is derived from the Greek word *arsenikon*, meaning potent. Fowler's solution, a 1% arsenic trioxide preparation, was used widely during the nineteenth century in various medical conditions [1,2]. In fact, before penicillin was discovered arsenic was one of the primary treatments for syphilis [1]. Along with its use in medicine, arsenic was common in makeup and pigments. Paints with copper acetoarsenite pigment were known commonly as Paris green. Frank Capra's film *Arsenic and Old Lace* presented arsenic as the perfect poison. In the film, two ladies use arsenic powder as part of a concoction added to elderberry wine to poison lonely old men and transients. Commonly known as aqua toffana after the famous 18th century poisoner Madame Guilina Toffana, mixtures of arsenic have provided a ready means of criminal poisoning throughout history and have been suspected in many famous deaths, including Mozart [3] and Napoleon [4]. Although its physical properties place arsenic in the category of metalloids, its similar pathophysiology and toxicity often result in its being categorized as a heavy metal in clinical papers. In industry, arsenic has been used to manufacture paints, fungicides, insecticides, pesticides, herbicides, wood preservatives, and cotton desiccants. Arsenide crystals, such as aluminium gallium arsenide, are common components of semiconductors and electronic devices [5]. Medicinally, arsenic trioxide is used to induce remission in patients who have acute promyelocytic leukemia [6] and is a common constituent or contaminant of many nonwestern traditional medicine remedies. Most cases of acute arsenic poisoning occur from accidental ingestion of arsenic-containing pesticides and less commonly from attempted suicide or homicide [5,7]. The major cause of chronic human arsenic toxicity is from geological contamination

of drinking water, with tragic examples recently demonstrated in Bangladesh and West Bengal, India [8,9].

Toxicity

Arsenic compounds occur in three oxidation states: trivalent arsenite, pentavalent arsenate, and elemental. Arsenite is ten times more toxic than arsenate; elemental is nontoxic. Arsenic also exists in three chemical forms: organic, inorganic, and arsine gas, with organic arsenic having little acute toxicity whereas inorganic arsenic and arsine gas are toxic [10]. Exposure to arsenic primarily occurs by ingestion, but inhalation and absorption through the skin are possible. Arsenic occurs naturally in seafood as nontoxic organic compounds, such as arsenobetaine, which can cause elevated urine arsenic levels [11,12].

The lethal dose of inorganic arsenic has been estimated to be 0.6 mg/kg [5,13]. After absorption, inorganic arsenic rapidly binds to hemoglobin in erythrocytes [14]. Blood arsenic is redistributed quickly (within 24 hours) to the liver, kidneys, heart, lungs, and to a lesser degree the nervous system, GI tract, and spleen. Arsenic undergoes hepatic biomethylation to form monomethylarsonic and dimethylarsinic acids that have less acute toxicity. A small amount of inorganic arsenic also is excreted unchanged [15–17]. About 50% of ingested arsenic can be eliminated in the urine in three to five days with residual amounts remaining in the keratin-rich tissues, such as nails, hair, and skin [5].

Depending on its oxidative state arsenic poisons cells by one of two key mechanisms [18]. By binding the sulfhydryl groups on critical enzymes, trivalent arsenite depletes lipoate, which is involved in the synthesis of key intermediates in the Krebs cycle. Lipoate depletion results in inhibition of the Krebs cycle and oxidative phosphorylation leading to ATP depletion [19]. Pentavalent arsenate, on the other hand, can replace the stable phosphate ester bond in ATP with the arsenate ester bond rapidly hydrolyzing (arsenolysis) uncoupling oxidative phosphorylation and depleting ATP stores [14]. The combination of inhibiting cellular respiration and uncoupling oxidative phosphorylation results in cellular energy depletion, resulting in cell death in high energy dependent tissues [18].

In acute arsenic poisoning, the clinical features initially are GI, including nausea, vomiting, abdominal pain, and bloody rice water diarrhea [10,20,21]. Hypovolemic shock may follow in severe cases as a result of endothelial damage and third spacing of fluid [22]. Hematologic abnormalities, including bone marrow depression, pancytopenia, anemia, and basophilic stippling, usually appear within 4 days of large ingestions [23]. QT interval prolongation and ventricular arrhythmias, such as torsade de pointes, can occur several days after initial improvement in GI symptoms [24,25]. Neurologic manifestations include a distal symmetric peripheral neuropathy commonly presenting with burning and numbness in the hands and feet

[26,27]. In cases of severe poisoning, however, a syndrome of rapidly developing ascending weakness similar to Guillain-Barré may be seen [28,29]. Along with the peripheral nervous system, the central nervous system may be affected, with the development of encephalopathy [29].

In chronic arsenic exposure, a wide range of clinical features are seen [30]. Dermatologic changes include hyperpigmentation and keratosis on the palms and soles [31,32]. The nails may exhibit transverse white bands known as Mees lines (Fig. 1) [33]. Mees lines are the result of interruption of the nail matrix, can be seen in acute and chronic poisoning, and are not specific to arsenic. They may not be evident until weeks after the exposure and may not be present in all patients. Cardiovascular effects include an increased incidence of hypertension and peripheral vascular disease. Sporadic outbreaks of peripheral vascular gangrene known as black foot disease have occurred in Taiwan and have been linked to high levels of arsenic in the drinking water [34]. A stocking-glove distribution sensory greater than motor peripheral neuropathy is the most frequent neurologic manifestation of chronic arsenic toxicity [27]. Chronic arsenic exposure has been associated with various malignancies including skin, lung, liver, bladder, and kidney [35]. Inorganic arsenic crosses the placenta and may be teratogenic in animals [36].

Diagnosis

Diagnosis of arsenic poisoning is based on incorporating clinical presentation (history and physical findings) with history of exposure in the presence of elevated body burden of arsenic. Laboratory tests should survey multiorgan functions, including a complete blood count with smear and a comprehensive metabolic panel. Some arsenic compounds are radiopaque and visible on abdominal radiograph [37]. An electrocardiogram is indicated to assess the QT interval, which may be prolonged [24]. Nerve conduction testing typically shows evidence of distal symmetric sensorimotor axonopathy [27]. In massive ingestions, however, conduction slowing may be evident, resulting in the false diagnosis of Guillain-Barré [29].

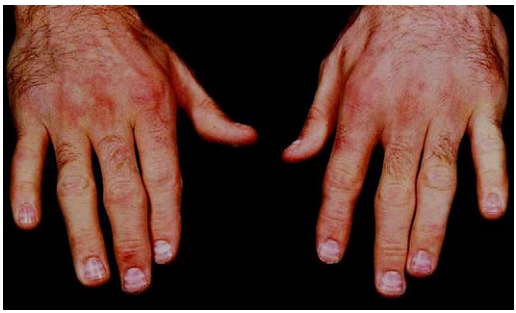

Fig. 1. Arsenic poisoning and Mees lines. (Courtesy of R. Pascuzzi, MD, Indianapolis, IN.)

The most important and reliable diagnostic test is a quantitative 24-hour urinary arsenic excretion [5,10]. Normal values are less than 50 μg/L. Recent seafood ingestion, however, may cause significantly elevated urinary arsenic values, and speciation of the urinary arsenic can be performed to differentiate inorganic from organic forms [12]. Although blood arsenic may be elevated initially in the acute poisoning, levels rapidly decline in the next 24 to 48 hours despite continued symptoms and increased urinary arsenic excretion. Whole blood arsenic level is usually less than 1 μg/dL. Residual arsenic in hair and nails may persist for prolonged periods, but external contamination may render interpretation difficult and unreliable [38].

Management

Treatment of arsenic poisoning begins with the removal from the exposure source. Supportive measures and chelation therapy are the mainstays of management. Volume resuscitation is of paramount importance in the severely poisoned patient, and chelation with dimercaprol or succimer (2,3-dimercaptosuccinic acid, DMSA) should be considered in patients who have symptoms or increased body burden of arsenic [39–42]. Hemodialysis maybe considered for patients who have renal failure [43].

Arsine gas

Arsine gas is considered the most toxic of all arsenic compounds. It is a dense, colorless, nonirritating gas with a garlic-like odor. It has poor warning characteristics allowing for significant exposure and toxicity to occur before detection [44]. Exposure to arsine gas occurs whenever inorganic arsenic-containing solutions or compounds are exposed to acids or nascent hydrogen. At-risk occupations include the smelting of metals and ores, galvanizing, and microelectronics semiconductor manufacturing [45].

Toxicity

Inhaled arsine gas rapidly diffuses into the bloodstream binding with RBCs and causing a rapid and severe Coombs negative intravascular hemolysis [46]. The mechanism of hemolysis is not elucidated fully, but is believed to involve oxidative stress and depletion of glutathione stores in the RBCs [47–54]. Along with hemolysis, arsine gas exposure causes acute renal failure [55]. The pathophysiology of oliguric renal failure from arsine is multifactorial, including direct toxic effects by arsine and arsenite on renal tubular cells, hemoglobin pigment deposition on the renal tubular cells, and tissue hypoxia secondary to severe hemolysis [56,57].

Between 2 and 24 hours following a significant exposure to arsine gas, patients present with general nonspecific symptoms, including malaise, fatigue, headache, dizziness, fever and chills, nausea, vomiting, and

abdominal pain [13,46,58–60]. Within 4 to12 hours, patients report dark red urine followed by oliguria or anuria, and by 24 to 48 hours of exposure a bronze discoloration of the skin may appear. The triad of abdominal pain, hemolysis, and hematuria are characteristic diagnostic features of arsine toxicity. Symptoms of sensorimotor peripheral neuropathy also may appear within weeks of exposure.

Diagnosis

Diagnosis of arsine gas poisoning is based on incorporating the clinical presentation (history and physical findings) with the history of exposure. The clinical triad of abdominal pain, hematuria, and hemolysis together with a history of recent potential occupational exposure is highly suggestive of arsine toxicity [13,46,58,59]. Laboratory tests, such as CBC with peripheral smear, serum chemistry, a negative Coombs test, decreased serum haptoglobin levels, and urinalysis, should help reveal and quantify the intravascular hemolysis. Even though blood and urine arsenic concentrations would be elevated following significant exposure to arsine gas, the diagnosis usually can be established by clinical presentation. Prompt treatment should not be delayed pending arsenic laboratory analysis.

Management

The first component of intervention following arsine gas poisoning is the removal from the source of exposure. In a severely poisoned patient who has evidence of hemolysis prompt whole blood exchange transfusion is of paramount importance based on case reports in the literature [13,46,50,55,58–63]. The benefits of exchange transfusion include restoring functional RBCs, clearance of hemoglobin pigment released by hemolysis (Fig. 2), and removal

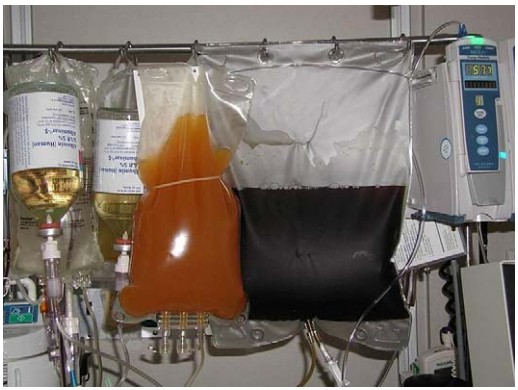

Fig. 2. Arsine hemolysis. The bag on the right represents the plasma removed from an arsine-poisoned patient compared with normal fresh frozen plasma on the left. (Courtesy of D. Rusyniak, MD, Indianapolis, IN.)

of toxic products formed as a result of arsine–hemoglobin reaction. Hemodialysis and exchange transfusion may be required if there is evidence of renal insufficiency [63]. Chelation with British anti lewisite does not appear to alter the natural history of arsine-induced hemolysis [7]. Because arsine poisoning produces significant arsenite concentrations chelation therapy might be of benefit [64]. It is not clear whether chelation therapy affects the evolution of peripheral neuropathy associated with arsine poisoning.

Thallium

Clinical scenario

After a weekend of work at a local automotive plant five middle-aged men simultaneously began to complain of pain and paresthesias in their feet. Over the next 10 days their symptoms progressed to include pain and numbness in the lower extremities and hands. In several of the men the pain was severe enough to make the weight of a bed sheet intolerable. Although the diagnosis eluded various physicians, the development of alopecia in these five men ultimately lead to testing for and diagnosis of acute thallium poisoning. A workplace investigation by Occupational Health and Safety Administration (OSHA) and criminal authorities ultimately revealed nine poisoned patients and the source of thallium to be the malicious contamination of two workroom coffee pots [65].

Background

Thallium is a heavy metal, the toxicity of which has been known since shortly after its initial discovery in the late 1800s. Before 1930, thallium's depilatory properties were used in treatment of scalp ringworm until reports of pediatric deaths resulted in its clinical abandonment [66]. Thallium salts are tasteless, odorless, water soluble, and rapidly and completely absorbed by the GI tract. These properties made them excellent rodenticides until outbreaks of accidental and criminal poisonings led to their removal from the United States market in 1975 [67,68]. Thallium continues to be used today in the manufacturing of optic lenses and semiconductors. Because of its rapid uptake and distribution in the myocardium, small nontoxic doses of radioactive thallium are likewise still used today in the detection of cardiac dysfunction. Despite its limited access to the general public, thallium persists as a significant source of accidental and intentional poisonings in humans and animals [65,69–75].

Toxicity

Thallium is absorbed rapidly from the GI tract with measurable urinary and fecal levels as early as one hour after oral administration [76]. Thallium has wide distribution throughout the organism with the highest

concentrations found in the kidney and the lowest in the serum, fat, and central nervous system. Secondary to its entero-entero circulation, the fecal removal of thallium serves as the primary means of elimination [76]. Several theories exist as to the mechanisms of thallium's toxicity in biologic systems. Because potassium and thallium are univalent cations with similar atomic radii, Tl+ (1.50 Å) and K+ (1.38 Å), thallium may interfere with K^+-dependent processes, including pyruvate kinase and Na+/K+ ATPase [77–79]. This interference results in a decrease in catabolism of carbohydrates and impaired ATP generation through oxidative phosphorylation [79,80]. Thallium's affinity for sulfhydryl groups also results in the inhibition of several sulfhydryl-containing enzymes, including pyruvate dehydrogenase complex, succinate dehydrogenase, hydrolases, oxidoreductases, and transferases [79]. The clinical manifestations of thallium poisoning vary depending on the dose, age of victim, and whether the exposure is acute or chronic. In general, however, the presentation of a rapidly progressive peripheral neuropathy with the development of alopecia accurately describes acute thallium toxicity. Dysesthesias and paraesthesias of the feet, and less commonly the hands, classically occur within 1 week of exposure. Hyperesthesias predominate in the feet and occur with weight bearing [65,81]. Moderate exposures may progress to significant sensorimotor peripheral neuropathies with sensory symptoms predominating [65]. Alopecia is the best-known complication of thallium poisoning (Fig. 3). The onset of alopecia generally begins about 2 weeks after exposure with complete alopecia occurring by 3 to 4 weeks. This latent period corresponds to the maturation period of the new epithelial cells of the hair matrix [82]. If patients survive, hair typically starts to regrow by the fourth month after poisoning and may be fine and occasionally unpigmented [65,83]. Alopecia typically involves

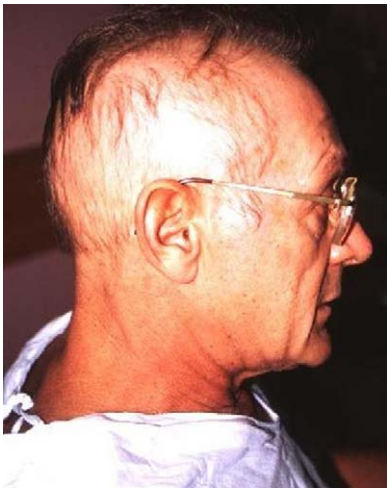

Fig. 3. Thallium-induced alopecia. (Courtesy of Daniel Rusyniak, MD, Indianapolis, IN.)

not only the scalp but also the lateral half of the eyebrows and the entire body, including pubic hair and axillary hair [82–85]. The cause of alopecia is not known but is believed to be either secondary to thallium interruption of cysteine in the synthesis of keratin or its ability to disturb energy metabolism in the growing cells of the hair matrix. Not all thallium-poisoned patients develop alopecia, and peripheral neuropathies can occur without its development [65].

Along with the neurologic and dermatologic manifestations of thallium poisoning, GI symptoms, including pain, diarrhea, and more commonly constipation, have been reported. Unlike arsenic, however, they do not dominate the early clinical picture. Other clinical manifestations of thallium poisoning include diffuse myalgias, pleuritic chest pain [65,67,72], insomnia, optic neuritis, hypertension, nonspecific ST-T wave changes, nail dystrophy (Mees lines), hepatitis, chronic neuropsychiatric manifestations [86], and cranial nerve deficits [87].

Diagnosis

Early diagnosis in thallium poisoning may be problematic because it is an uncommon poison with its initial symptoms often attributed to other causes [65]. Further complicating the early recognition of thallium poisoning is that alopecia, the most recognizable feature of thallium poisoning [73], may not be evident for up to 14 days [82]. Hair analysis may offer the potential for early diagnosis. In cases in which the hair of thallium-poisoned patients has been examined it has been found to be in anagen effluvium [82,88]. Other microscopic findings include dysplastic hair roots, changes in the diameter of the fiber, and a disorganized cortex, which appears dark under a light microscope [82]. The most interesting and perhaps diagnostic feature in acute thallium-poisoned patients is the finding of darkened hair roots when examined under a light-powered microscope (Fig. 4) [65,83]. This finding is reported to occur as early as 3 hours in rats and 4 days in humans after thallium poisoning [83]. The pigment is reported to be present in up to 95% of scalp hair and in 50% to 60% of chest and leg hair, but only 30% of tactile hair (eyebrows and eyelids) [83]. If poisoning occurs in repeated doses several bands can be seen, analogous to multiple Mees lines [83]. Although some investigators have suggested that the dark roots actually represent an accumulation of pigment [83], the cause of the blackened roots is not a pigment or the metal itself but rather an optical phenomenon. It is believed that in the hair root the disorganized matrix results in the accumulation of gaseous inclusions, which results in diffracting light and the appearance of a black stain [82,84]. When these hairs are treated with thioglycolic acid or mechanical pressure the gas bubbles have been noted to escape, with subsequent disappearance of the darkened strip [89].

Nerve conduction studies also may be a useful modality in diagnosing and monitoring patients who have thallium poisoning because the severity of abnormalities of nerve conduction studies seems to correlate with the

Fig. 4. Blackened hair root in a thallium-poisoned patient under light microscopy. (Courtesy of D. Rusyniak, MD, Indianapolis, IN.)

severity of other symptoms and findings [65]. In severe poisoning nerve biopsy may reveal Wallerian degeneration with axonal destruction and secondary myelin loss [87,90,91].

A definitive diagnosis of thallium poisoning, however, requires the identification of elevated thallium concentrations in urine or hair. As in other metals a 24-hour urine is considered the gold standard in thallium poisoning, with normal levels generally less than 20 μg per specimen. Hair also can be tested, with normal levels being less than 15 ng thallium per gram of hair [79].

Management

The primary objective in treating thallium poisoning is to increase its elimination and prevent further toxicity. Currently the best-studied and most effective antidote for thallium poisoning is Prussian blue. Prussian blue is a poorly absorbed complex of potassium hexacyanoferrate and is available in soluble (colloidal) and insoluble formulations [92]. Recently the insoluble formulation received approval from the US Food and Drug Administration as an antidote for cesium and thallium poisoning, although the soluble formulation may be more efficacious [79,92]. The current manufacturer-recommended dose of Prussian blue is 3 g orally three times a day with others recommending 250 mg/kg given two times a day [93]. Prussian blue's mechanism of action is through the exchange of potassium for thallium in the molecular lattice of the hexacyanoferrate complex resulting in the fecal excretion of a thallium–Prussian blue complex. Numerous animal studies show Prussian blue to decreased mortality, increase elimination, and decrease CNS thallium concentrations [94–101]. Good outcomes in a few

human case reports have supported the safety and efficacy of Prussian blue in thallium poisoning [71,72]. Prussian blue is an exceedingly safe compound with few if any reported cases of toxicity in either animal or human studies [102]. Based on thallium's affinity for sulfhydryl groups, several commonly used sulfur chelators have been used in models of poisoning but without significant improvement [101,103,104]. Because some hospitals may not carry Prussian blue some authors have recommended activated charcoal until Prussian blue is available. In vitro studies demonstrate excellent adsorbent properties of thallium with activated charcoal [105,106]. Although thallium's entero-entero circulation makes charcoal an excellent choice for treatment, animal studies are contradictory [95,103] and human data is largely anecdotal.

Mercury

Clinical scenario

A 14-year-old male presented to an outpatient clinic with the chief complaint of bilateral thigh pain. Over the preceding 8 weeks his mother had noticed his becoming withdrawn and currently described him "like a hermit". His physical examination revealed profuse sweating, tachycardia, hypertension, tremor, ataxia, and a desquamating erythematous rash on the palms, soles, toes, and fingertips. Although initially believed to have pheochromocytoma, a 24-hour urine mercury concentration was found to be 264 μg/L. Environmental testing of his house, a former TV repair shop, showed high levels of elemental mercury vapor. He was removed from the exposure and treated with oral DMSA chelation therapy with resolution of his rash and symptoms.

Background

Mercury is a naturally occurring metal, the name of which comes from the Greek word *Ὑδραργυρος* (hydrargyros), meaning water and silver. It exists in three forms, each with characteristic and distinct toxicities: elemental mercury, inorganic mercury salts, and organic mercury. Given its liquid, silvery appearance, the elemental form of mercury has also been called quicksilver or liquid silver [107]. Elemental mercury use was documented as early as 1500 BC in Egypt, where it was used to decorate the tombs of wealthy citizens [108]. Evidence of its use for cosmetic purposes was found in ancient Greece and Rome [109] and it has been used for medicinal purposes in Eastern Asia for centuries. In the 1400s mercury was used in Western Europe as a syphilitic, and is the origin of the phrase "two minutes with Venus, two years with mercury" [110]. Until the late 1800s, a tablespoon of quicksilver was a commonly used laxative in children [107], but the medicinal use of mercury largely fell out of favor by the nineteenth century when it was first

suspected of causing toxic effects [108–110]. Reliance on mercury during the industrial revolution, however, resulted in increased workplace exposure. The most striking example of this occurred among hat makers, who combed elemental mercury through animal fur to prepare the fibers for use in felt production, a process called carroting. The term carroting came from to the orange hue the fur took on during this process. A large number of hatters developed mercury toxicity, resulting in the common phrase "mad as a hatter" [107].

Elemental mercury

Elemental mercury is one of only two metals that are known to be liquid at room temperature [111]. It is a heavy, nonwetting liquid that is able to volatilize to an odorless gas in quantities sufficient to cause clinical toxicity at room temperature [112]. Its uniform expansion over a wide range of temperatures and its ability to alloy easily with other metals led to mercury's use in several commercial applications [109], including thermometers, barometers, thermostats, electronics, batteries, dental amalgams, home folk remedies, and a host of other uses [109,113]. Because of recent concerns regarding exposure and toxicity, the use of mercury in the manufacture of most of these products has been abandoned in favor of less toxic substances [109]. Many older mercury-containing products are still in use, however, and continue to be a source for potential toxicity.

Toxicity

Exposure to elemental mercury occurs by way of inhalation of the vapor, ingestion of the liquid, or cutaneous exposure. Intravenous mercury injection is a rare route of exposure in cases of attempted self-harm [114]. Ingestion of elemental mercury rarely is of clinical consequence. The metal is poorly absorbed in the gut and is eliminated in the feces [108,109,113]. Although in patients who have normal GI mucosa toxicity rarely develops after ingestion, patients who have abnormal GI mucosa may absorb enough mercury for toxicity to occur [115]. Occasionally mercury becomes trapped within the appendix, but without signs of mercury toxicity or appendicitis it can be safely monitored and allowed to pass on its own [116,117]. If vomiting with subsequent aspiration of elemental mercury occurs the risk for toxicity is increased because mercury is well absorbed within the lungs [113]. In most cases cutaneous exposure also is of little clinical consequence [112] with the main risk to individuals who handle elemental mercury being inhalation of the vapor rather than direct contact with the metal. Toxicity from elemental mercury occurs from inhalation of the vapor because mercury is well absorbed into the pulmonary circulation allowing distribution to the brain, kidneys, gut, and lungs [108,112,113]. Elemental mercury readily crosses the blood–brain barrier where it concentrates in neuronal lysosomal dense bodies [108]. Mercury combines with sulfhydryl groups on cell membranes

and interferes with numerous cellular processes, including protein and nucleic acid synthesis, oxidative stress, calcium homeostasis, and protein phosphorylation [118].

The manifestations of elemental mercury toxicity have great variability depending on the chronicity of the exposure. Acute toxicity may manifest within hours of a large exposure with GI upset, chills, weakness, cough, and dyspnea, with severe cases developing adult respiratory distress syndrome [119] and renal failure [120]. Chronic mercury toxicity may develop over a period of weeks to months, depending on the level of exposure. Initial symptoms commonly include GI upset, constipation, abdominal pain, and poor appetite, and may mimic a viral illness [108,121]. Other symptoms include dry mouth, headache, and muscle pains [108,113,121]. Chronic exposure results in two distinct clinical syndromes, acrodynia and erethism [108,113,121]. Known as pink disease, Feer syndrome, Feer-Swift disease, erythroderma, and raw-beef hands and feet [113,122,123], acrodynia is a complex of symptoms occurring in chronic toxicity from elemental and inorganic mercury. It occurs more commonly in infants and children, but has been reported in adults [113,124]. Characteristic findings include sweating, hypertension, tachycardia, pruritus, weakness, poor muscle tone, insomnia, anorexia, and an erythematous, desquamating rash to the palms and soles (Fig. 5) [108,112,113,121]. Oral findings including reddened, swollen gums, subsequent mucosal ulcerations, and possible tooth loss [108,113,123]. By an unknown mechanism, mercury may result in proximal weakness primarily involving the pelvic and pectoral girdle [113,121]. Patients who have mercury poisoning often develop characteristic personality changes collectively termed erethism. These patients may exhibit memory loss, drowsiness, withdrawal, lethargy, depression, and irritability [113]. Another common finding in mercury poisoning is incoordination and a fine motor intention tremor primarily involving the hands [125,126]. It has been suggested that erethism may be a Parkinsonian-like syndrome involving the basal ganglia and cerebellum, though dose relationships have not been shown clearly [113].

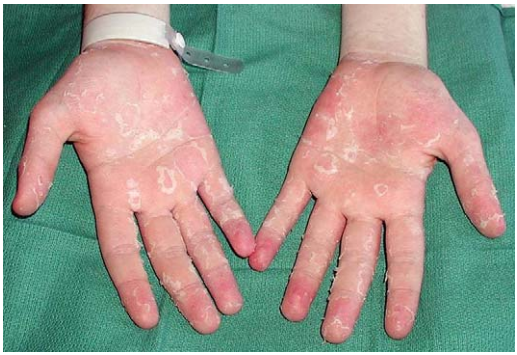

Fig. 5. Acrodynia from elemental mercury. (Courtesy of D. Rusyniak, MD, Indianapolis, IN.)

Whether these changes are reversible with the removal of the offending agent remains unclear also. The sweating, tremor, hypertension, and tachycardia associated with acrodynia may mimic the presentation of pheochromocytoma [127–129]. These patients often are misdiagnosed early in their clinical course, and while the patient is worked up for neuroendocrine disease the diagnosis of mercury toxicity may be delayed [127]. Mercury inhibits the enzyme catechol-*o*-methyltransferase by inactivation of the coenzyme S-adenosylmethionine, producing elevated levels of catecholamines in the body [127–129]. The increase in catecholamines results in hypertension, sweating, and tachycardia that may be clinically indistinguishable from pheochromocytoma. A 24-hour urine collection on these patients reveals elevated levels of urinary catecholamines, although typically to a lesser degree than that seen in true neuroendocrine disease [129]. This finding suggests that mercury toxicity should be considered in the differential for any patient presenting with symptoms of pheochromocytoma.

Diagnosis

The diagnosis of elemental mercury poisoning involves incorporating clinical presentation (history and physical findings), history of exposure, and an elevated body burden of mercury. Blood mercury levels have limited usefulness because of mercury's short half-life in the blood [108,112]. Whole blood mercury concentrations typically are less than 10 μg/L. Urine levels are obtained more commonly in chronically exposed patients, with 24-hour collections more reliable than spot urine levels. Normal levels typically are less than 50 μg of mercury in a 24-hour period [108,113]. Patients undergoing chelation therapy at the time of collection have elevated levels of mercury in a 24-hour sample making interpretation difficult if not impossible [130].

Management

Removal of the patient from the source of the toxic exposure is the most important intervention [63,108,112,113,121]. Because elemental mercury typically has minimal toxicity when ingested, there is little role for GI decontamination.

Although chelation therapy is considered the mainstay of treatment several controversies remain regarding its use. Chelators are charged molecules capable of binding the metal ion forming a neutral complex excreted by the kidney [112]. The goal of chelation therapy is to reduce the total body burden of heavy metal. Several agents are available, the most commonly cited including succimer, dimercaprol, and D-penicillamine [63]. Patients may require chelation for several months depending on the total body burden of mercury. The usefulness of chelation therapy remains unclear, because there is a lack of studies showing a clear long-term benefit in patients treated with this therapy [112,131]. In patients who have developed renal failure, hemodialysis may be required, with or without the inclusion of a chelation agent.

Inorganic mercury

Inorganic mercury occurs naturally as mercuric and mercurous salts, the most common being mercury(II) sulfide (HgS), also known commonly as cinnabar and vermillion. This red, earthy-appearing ore also is found in a crystal form prized for its rich red color, and was equally prized as a source of mercury throughout its history [132]. Other common mercurial salts include mercuric chloride, mercuric oxide, mercuric sulfide, mercurous chloride, mercuric iodide, ammoniated mercury, and phenylmercuric salts [108,113]. Historically, these compounds have been used in cosmetics and skin treatments, particularly as skin-lightening agents [113,133]. Mercurial teething powders containing calomel (mercuric chloride) were in common use until the mid-twentieth century and were prescribed to infants to soothe the discomfort of teething [122]. Although these treatments no longer are prescribed, some dermatologic preparations still are available over the counter in the United States [113]. Patients also may develop local or systemic toxicity after using mercurial compounds found in old topical antiseptics, skin creams, and folk remedies. Currently, most exposures in the United States occur from exposure to germicides, pesticides, and mercury-containing antiseptics [113].

Toxicity

Inorganic mercury is absorbed readily by multiple routes, including GI, inhalational, and dermal. Ingestion typically results in the greatest degree of absorption, followed by inhalational and dermal, but the absolute amount of mercury absorbed depends on the degree of exposure. In contrast to elemental mercury, inorganic mercury is severely corrosive to the GI mucosa [63,113,134]. Patients may present acutely after ingestion of mercurial salts complaining of oral pain or burning, nausea, vomiting, diarrhea, hematemesis, bloody stools, or abdominal discomfort [113,134]. Frank colitis with necrosis or sloughing of the GI mucosa may develop with severe toxicity [108,134]. In some cases, volume loss from GI losses or hemorrhage may require large volume fluid resuscitation. Because mercury salts are absorbed through the GI mucosa [135] significant blood levels can be achieved after ingestion, with resultant systemic toxicity.

Prolonged use of topical preparations containing mercury can result in several cutaneous changes, including worsening of hyperpigmentation, swelling, and a vesicular or scaling rash [113]. Hyperpigmentation manifests as a gray-brown discoloration in the skin and is most pronounced in the skin folds of the face and neck [113]. Topical use of calomel (mercuric chloride) on the oral mucosa was common in the nineteenth and early twentieth centuries and was associated with development of loose teeth, bluish discoloration of the gums, and systemic toxicity [113,122]. Contact stomatitis or irritation of the oral mucosa from dental amalgams has been reported also and may represent an allergic reaction [136–138]. Inorganic mercury is absorbed readily through the

skin, so patients may develop systemic mercury toxicity even if using only topical preparations [113]. Inorganic mercury has a half-life in the blood of 24 to 40 days with mercurial ions being excreted by the kidneys and resultant concentration of mercuric and mercurous ions in the renal tissues [108]. Acute renal failure may develop because of the toxic effect of mercury on the renal tubular cells with the proximal tubular cells being particularly susceptible to injury, although the mechanism remains unclear [139]. Acute tubular necrosis may develop up to two weeks after exposure. Cases of nearly complete recovery have been reported, however, even after prolonged renal failure [140].

Chronic inorganic mercury exposure can cause membranous glomerulonephritis and nephrotic syndrome [141]. The mechanism for this injury is unclear, although animal studies suggest that it may be related to an immune-modulated process with production of autoantibodies against components of the glomerular basement membrane [141]. In some cases the nephrotic syndrome has resolved spontaneously with removal of the offending agent [141]. Like elemental mercury, inorganic mercury can cause acrodynia and erethism [108,113].

Diagnosis

Diagnosis of inorganic mercury poisoning is the same as that of elemental mercury poisoning, with 24-hour urine testing being the gold standard.

Management

The target organs of acute inorganic mercury poisoning are the GI tract and the kidneys. The corrosive injury to the GI tract in serious inorganic mercury ingestion may necessitate aggressive volume resuscitation. Also, prompt and expedient chelation is critical in preventing or reducing renal injury. Dimercaprol has been reported to be most effective if administered within 4 hours of inorganic mercury ingestion, but succimer may be substituted for dimercaprol once patients are able to tolerate oral intake. Hemodialysis is indicated in oliguric or anuric renal failure because it may contribute to the elimination of dimercaprol–Hg complex.

Organic mercury

Although the toxicity of elemental and inorganic mercury has been known for centuries, toxicity from organic mercury was not appreciated fully until several large outbreaks brought it to the forefront of environmental toxicology. Of the organic mercurial compounds, methylmercury has resulted in the largest number of poisonings. Used primarily as preservatives, antiseptics, and in seed dressings, organic mercurial compounds were used commonly for industrial and medicinal purposes in the early twentieth century. Merbromin (mercurochrome) still is used today as a topical antiseptic and ethyl mercury

(thimerosal) was only recently removed from multidose vaccine vials. Today the most common source of organic mercury exposure, however, is dietary consumption of predatory fish. Through a process known as bioamplification, soil and marine microorganisms methylate inorganic and elemental mercury from industrial waste ultimately resulting in methylmercury concentrating in the tissues of large predatory fish, such as tuna and swordfish. In 1956 people in the Japanese finishing village of Minamata were stricken with a mysterious illness primarily affecting the central nervous system [142,143]. Secondary to the rising costs of recycling, a local industrial company had begun dumping mercury-laden waste directly into the bay [144], ultimately resulting in greater than 100 tons contaminating the waters and marine life for decades [145]. In total, methylmercury contamination in Japan resulted in 2263 cases of adult and 63 cases of congenital organic mercury poisoning [146]. A similar outbreak occurred in Iraq in 1972, at which time more than 6000 people were poisoned and 459 died after eating grain treated with a methylmercury fungicide that had been made into bread instead of planted [147].

Toxicity

Unlike the elemental and inorganic forms, organic mercury is well absorbed by the GI tract with greater than 90% of an ingested dose absorbed [148]. Likewise, organic mercury readily crosses the blood–brain barrier and the placenta. Once absorbed, organic mercury is distributed from the blood into the brain reaching levels three to six times those of the blood [149]. Organic mercury poisoning most commonly presents with clinical findings of marked concentric constriction of the bilateral visual fields, paresthesias of the extremities and mouth, ataxia, incoordination, tremor, dysarthria, and auditory impairments [142,147]. Autopsy findings commonly consist of neuronal damage in the gray matter of the cerebral and cerebellar cortex with the most-affected areas being the calcarine region of the occipital lobe and the pre- and postcentral and temporal cortex. In the cerebellum there is loss of granule cells typically with preservation of the neighboring Purkinje cells [142,146]. Along with the damage to the central nervous system peripheral nerve damage, largely in the sensory fibers, can occur [146,150].

One of the most devastating effects of methylmercury exposure in Japan was on children born to exposed mothers, who developed a syndrome similar to cerebral palsy [151] termed congenital Minamata disease. Symptoms seen in cases of congenital Minamata disease included mental retardation (100%), primitive reflexes (100%), cerebellar ataxia (100%), limb deformities (100%), dysarthria (100%), chorea (95%), hypersalivation (95%), and microcephaly (60%) [142,144,151]. The incidence of congenital Minamata disease between 1955 and 1958 in the Minamata area was estimated to involve as many as 29% of children born to exposed mothers [151]. Pathologic changes in congenital Minamata disease are similar to the adult form, with general atrophy of the cortex, hypoplasia of the corpus callosum,

demyelination of the pyramidal tracts, and hypoplasia of the granula cell layer of the cerebellum [151]. Likewise in the Iraqi grain outbreak severe neurologic deficits were noted in children born to exposed mothers, including mental retardation and blindness [152]. To date, Minamata represents the best example of the sensitivity and risk for the developing central nervous system to methylmercury. More recently, ethyl mercury used as a preservative in vaccines has been a subject of intense debate as a possible cause of autism and other developmental disorders. Epidemiologic studies, however, have not established a link between mercury and autism [153].

Diagnosis

As with elemental and inorganic mercury poisoning, making the diagnosis of organic mercury poisoning requires recognition of the clinical effects with corroborating mercury levels in the person or the environment. Unlike inorganic and elemental poisoning, organic mercury is identified best in victims by analysis of whole blood or hair [147,152]. In the blood more than 90% of methylmercury is bound to hemoglobin within the RBCs [148]. Because methylmercury is eliminated primarily in the bile, urinary mercury levels are unreliable. Normal values for whole blood mercury typically are less than 0.006 mg/L, but diets rich in fish can increase blood mercury levels to as high as 0.200 mg/L or higher [154]. In the Iraq grain disaster, whereas the amount of mercury consumed was correlated strongly with blood levels and symptoms, there was wide individual variability with respect to blood levels and symptoms [147].

Management

The treatment of organic mercury poisoning requires early recognition and removal of the source. For those patients who have significant symptoms or exposures various chelating agents have been tried including D-Penicillamine, N-acetyl-D-L-penicillamine, 2,3-dimercaptopropane sulphonate, and succimer [147,152,155]. Although all treatments are believed to decrease whole blood mercury concentrations [156] no clinical studies have demonstrated appreciable clinical improvement. Because most cases are not identified until appreciable symptoms have developed it is unclear what role early chelation might play on outcomes. Animal studies have suggested that chelation reduces brain mercury concentrations but has to be administered early in the poisoning to see improved outcomes [157,158].

Lead

Clinical scenario

A 2-year-old white male presented to the emergency room with lethargy. He had not been to his pediatrician in the last year, but had reached all of

his developmental milestones. Along with the lethargy the parents described him as being irritable and less interested in playing with his toys over the last two months. His father worked at a factory and the family lived in an urban area in a house that was built in the 1950s. On examination the patient had a depressed level of consciousness without focal neurologic findings. During the patient's workup for altered mental status a blood lead level was measured at 145 μg/dL. CT of the brain showed mild cerebral edema and blood work showed a microcytic anemia. A flat-plate radiograph did not show any foreign bodies. On admission the patient was started on oral succimer and intravenous CaEDTA. Two days later the patient's blood lead level was down to 60 μg/dL and his mental status had improved greatly. He was discharged from the hospital and continued on a 3-week course of oral succimer. The Department of Public Health evaluated the child's house and noticed teeth marks along many of the windowsills throughout the house. After removal of the lead paint from the house, the patient continued to have fluctuating lead levels for the next 3 years ranging from 10 to 45 μg/dL and received several more courses of oral succimer. His pediatrician reports his developmental progress is slightly delayed.

Background

A gray-silver heavy metal comprising approximately 0.002% of the earth's crust, lead has various industrial uses but no physiologic use. Any evidence of lead within the human body, therefore, can be viewed as contamination. The earliest evidence of lead use by humans dates back to 40,000 BC, found in paints at Neanderthal burial sites. Many prominent ancient cultures have mined lead, including the ancient Egyptians, Hebrews, Phoenicians, Greeks, and Romans [159]. The Industrial Revolution resulted in an increase in lead machinery used in the workplace and lead products distributed to consumers. Leaded gasoline and lead-based paints were two common forms of lead that achieved widespread use starting in the early twentieth century [159]. Today the only metal with more commercial use than lead is iron. The first written records of lead toxicity were by the ancient Egyptians. Historians speculate that the personality changes of the leaders of Rome, along with sterility and stillbirths, could have been a direct effect of lead toxicity [160]. Lead continued to cause medical problems throughout the ages. In 1763, Benjamin Franklin recognized abdominal colic and peripheral neuropathy as two consequences of chronic lead exposure. It was not until 1972, however, that the United States passed a law banning residential use of lead paint. Leaded gasoline, first used in the 1920s for its antiknock effects, has led to the contamination of air, soil, and crops. In the early 1990s leaded gasoline was no longer used in the United States, but continues to be a source of lead pollution in nondeveloped countries [159].

Modern occupational exposure is the main source for plumbism in adults. The main route of occupational toxicity is through respiratory

exposure. The occupations that are associated with the highest risk for lead poisoning are battery plant workers, metal welders, painters, construction workers, crystal glass makers, firing-range operators, shipbuilders, and lead miners [161,162]. Our present-day environment also is a source of lead. Houses built before 1978 commonly were painted with lead-based paint and are a major source of lead exposure, especially in the urban pediatric population. Leaded paints deteriorate and cause contamination of surrounding dust and soil. Older plumbing also may contain lead and can cause lead exposure through tap water [161].

Toxic lead levels also can result from the lead contained in many modern products, such as retained lead bullets, curtain weights, lead-glazed ceramics, and lead fishing weights [1,163]. Most lead toxicity from lead-containing products is a result of misuse, such as ingestion. Some folk remedies used in some Hispanic populations, such as azarcon and greta, still contain lead [161].

Pediatric toxicity

Young children use hand-to-mouth activity to explore their environment. Children who live in an environment that is contaminated with lead (ie, those who live in and around houses with lead-based paints) are more likely to suffer the effects of lead poisoning [161]. Children are at the greatest risk for accidental ingestions, including lead-based objects, around the age of 2 years. Children are more at risk for lead exposure during the summer months, which may be a result of increased amounts of lead-containing dust and increased child activity during these months [164].

The most common childhood presentation of lead poisoning is central neurotoxicity. Although blood lead levels cannot be correlated strictly with symptoms, there tend to be some cutoff values that are predictive of certain features. At lower levels (1–50 μg/dL) lead may cause subtle cognitive and behavioral changes difficult to differentiate from normal developmental variance [165]. At moderate levels (50–70 μg/dL) children may display a global decrease in activity, presenting as a children who do not enjoy playing or who developmentally fall behind their peers. These symptoms have been classified as pre-encephalopathic symptoms and are most prominent between 1 and 5 years of age. With severe lead toxicity (>70 μg/dL) children may be encephalopathic with coma, seizures, altered mental status, and symptoms consistent with increased intracranial pressure [1,166]. Encephalopathy from lead occurs most commonly between the ages of 15 and 30 months.

Although there is no debate as to the harmful effects of high lead levels, there is continued controversy over the effects of low lead levels on childhood cognitive development. Although studies have shown a relationship between increased lead levels and decreased IQ [165], critics of these studies have pointed out that the design and number of confounders in these studies

prohibit the proof of direct causality. Other symptoms of childhood lead toxicity include anemia; peripheral motor neuropathy; GI complaints, such as anorexia, vomiting, and abdominal pain; and growth delay. Lead readily crosses the placenta and has been reported to cause fetal toxicity [161].

The primary route of lead exposure in children is through the GI tract [161]. Lead probably is taken up at calcium absorption sites, which have increased activity at times of rapid growth [167].

The central neurotoxicity caused by lead is caused by disruption of the intercellular junction that seals the capillary endothelium. The mechanism of this disruption is interference with cellular calcium metabolism and second messenger signaling systems. With the loss of its tight seal, the blood–brain barrier is less effective and the capillaries leak, resulting in an increase in intracranial fluid and a resultant increase in intracranial pressure. This effect of lead is more prominent in young children because of their immature blood–brain barrier before the exposure [167,168].

Chronic exposure to lead affects numerous neurotransmitter systems, increasing the spontaneous release of dopamine, acetylcholine, and gamma-amino butyric acid; blocking N-methyl-D-aspartate glutamate receptors; and increasing levels of the intracellular messenger protein kinase C [161]. These effects result in an increase in random synaptic signals, termed synaptic noise, and a decrease in the ability of the neuron to produce a synaptic signal in response to a true stimulus. A human has the most neurologic synapses at the age of 2, after which the body, through apoptosis, rapidly starts to prune faulty and unnecessary synapses. The determination of whether a synapse is kept or destroyed is related to feedback from neurotransmitters and neurotransmitter receptors. Because lead interferes with neurotransmitters and their receptors it results in a disruption of synapse formation and synapse destruction [168].

Lead has two main toxic effects on the hematologic system: reduction of erythrocyte lifespan and decreased hemoglobin biosynthesis [169]. Lead causes inhibition of pyrimidine-5′-nucleotidase and inhibition of Na+-K+-ATPase leading to decreased energy use by the erythrocyte and a decrease in cell membrane stability. Pyrimidine-5′−nucleotidase is necessary for the removal of degraded RNA, and its inhibition by lead causes erythrocytes to form clumps, giving the cells the classic basophilic stippling appearance. Lead interferes with several enzymes in the heme synthesis pathway, including aminolevulinic acid synthetase, δ-aminolevulinic dehydratase (ALA-D), ferrochelatase, and coproporphyrinogen decarboxylase. ALA-D in particular can be inhibited by minimal lead exposure [161].

Diagnosis

Blood lead levels are the best indicator of lead exposure. Venous blood samples are necessary because capillary samples can give false positives because of skin contamination [1]. All children who fit into a high-risk

category (mainly based on socioeconomic factors) should be screened with a blood lead level at 1 and 2 years of age [1]. A complete blood count may show a hypochromic microcytic anemia and stippling of the RBCs [1].

Management

The most effective treatment for lead toxicity is removal of the patient from the lead-containing environment and cessation of exposure. Pediatric patients who present with symptoms of lead encephalopathy or with blood levels greater than 70 μg/dL should be considered candidates for parenteral chelation therapy with either dimercaprol or succimer and CaNa2EDTA [170]. Chelation with oral succimer should be considered in children who are asymptomatic with blood lead levels between 45 and 69 μg/dL [1,171]. Two recent studies have shown no neurologic benefit from chelation for children with blood lead levels between 20 and 44 μg/dL, and based on these studies chelation is not recommended for levels less than 44 μg/dL [172,173]. Children who present with lead foreign body ingestion may also benefit from cathartics, whole-bowel irrigation, or endoscopic removal [163].

Adult toxicity

Most adult lead poisonings occur from occupational respiratory exposures. Lead-induced hypertension is the most common symptom attributed to lead exposure in adults, but patients can also develop anemia, gastric colic, muscle and joint pain, decreased fertility, renal failure, and peripheral motor neuropathy [174]. Rarely, adults with blood lead levels greater than 100 μg/dL present with encephalopathy [175]. Adults more commonly suffer from subtle neurologic deficits, such as fatigue and emotional lability, after lead exposure. The main mechanism of lead-induced hypertension seems to be related to changes in vascular smooth muscle because of increased activity of the Na+–Ca+ exchange pump and interference of Na+–K+ ATPase activity. Lead-induced gastric colic may have a similar mechanism to that of vascular hypertension, with increased contractility of vascular smooth muscle. The progressive development of renal failure may result after long-term environmental exposures or the chronic release of deposited bone lead. Lead disrupts mitochondrial phosphorylation and oxidation within the kidney, leading to a decrease in energy-dependent transport. The end result of this disrupted transport is phosphaturia, glycosuria, and aminoaciduria [161]. With chronic lead exposure the kidneys are found to have lead–protein complex inclusion bodies [161]. There is some evidence that these inclusion bodies are the main pathway for lead excretion. As chronic lead exposure progresses fewer of these inclusion bodies are seen, and the renal tubules begin to show signs of intersitial fibrosis [161]. Peripheral neuropathy from lead exposure is caused by Schwann cell destruction followed by demyelination and axonal atrophy. Upper extremity motor neurons are more susceptible

to damage from lead than sensory or lower extremity neurons, resulting in the classic, albeit rare, presentation of bilateral wrist drop [176].

Lead's total body burden is stored mainly in bone, with 70% of a child's and 95% of an adult's total body burden stored in bone [174]. Within bone there are two main storage areas: the cortical bone, which is a stagnant store, and the trabecular bone, which is a more bioavailable store. Blood lead levels may increase during times of increased bone metabolism during pregnancy, osteoporosis, and fractures. The half-life of lead in human bone is estimated to be up to 30 years [177]. Lead objects retained within the body can serve as an artificial store of lead. The exposure of the object to an acidic environment in synovial or gastric fluid and mechanical stresses to the object within a joint space can cause increased systemic absorption of lead (Fig. 6) [178].

Diagnosis

Lead toxicity should be considered in the differential in anyone who displays unexplained hypertension, encephalopathy, peripheral motor neuropathy, gastric colic, and renal failure. Adults with histories of large exposures as children may also warrant screening because of the long half-life of lead in bone. OSHA guidelines mandate periodic screening for workers exposed to air lead levels of 30 $\mu g/m^3$ for 30 days or more. Workers with blood lead levels greater than 60 μg/dL or three consecutive levels greater than 50 μg/dL should have a repeat level every month, those with a level between 40 and

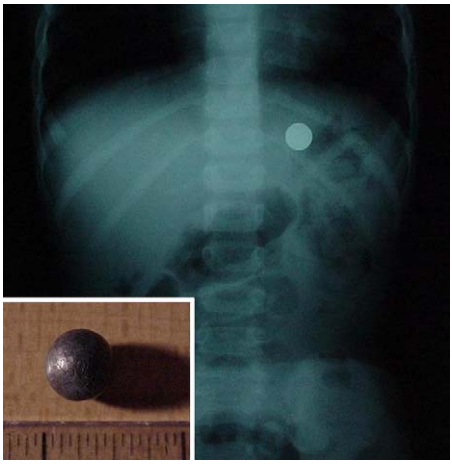

Fig. 6. A 3-year-old swallowed a lead musket ball at daycare (*inset*). A radiograph revealed the ball retained in the stomach. The lead ball was removed by endoscopy without complication. A venous blood lead level approximately 48 hours postingestion was 89 μg/dL. The child was treated with a course of succimer, and a repeat lead level 1 week after chelation was 5 μg/dL. The child never developed symptoms. (Courtesy of C. Holstege, MD, Charlottesville, VA.)

60 μg/dL should have a repeat level every 2 months, and those with elevated levels less than 40 μg/dL should have repeat levels every 6 months [162]. Currently the best screening test is a venous blood lead level. A complete blood count may show a hypochromic microcytic anemia and red blood cell stippling. A urinalysis and basic metabolic panel may be used to screen for renal toxicity. X-ray fluorescence technology may be a useful screening test in the future to determine bone lead burden; however, at this time it primarily serves as a research tool [179].

Management

The most effective therapy is limitation of exposure. In the workplace this may include using personal protective gear, improving industrial engineering, and adhering to safe work practices [162]. Chelation usually is reserved for adults who are symptomatic or who have a blood lead level greater than 70 μg/dL. Mildly symptomatic patients who have levels between 70 and 100 μg/dL may require a course of oral succimer, whereas those patients who have encephalopathy or levels greater than 100 μg/dL require intramuscular dimercaprol or oral succimer and intravenous CaNa2EDTA. A pregnant patient who has elevated lead levels should be treated using the same standards as a nonpregnant adult.

Summary

Acute and chronic toxicities from exposure to heavy metals are uncommon but pose significant morbidity and mortality if unrecognized. Diagnosis of heavy metal poisoning is based on incorporating clinical presentation (history and physical findings) with history of exposure in the presence of elevated body burden of the particular heavy metal. The key to managing heavy metal intoxication is the removal from offending exposure and the reduction of total body burden.

References

[1] Jolliffe DM. A history of the use of arsenicals in man. J R Soc Med 1993;86:287–9.
[2] Waxman S, Anderson KC. History of the development of arsenic derivatives in cancer therapy. Oncologist 2001;6(Suppl 2):3–10.
[3] Hirschmann JV. What killed Mozart? Arch Intern Med 2001;161:1381–9.
[4] Lin X, Alber D, Henkelmann R. Elemental contents in Napoleon's hair cut before and after his death: did Napoleon die of arsenic poisoning? Anal Bioanal Chem 2004;379:218–20.
[5] Yip L, Dart R. Arsenic. In: Sullivan JB, Krieger GR, editors. Clinical environmental health and toxic exposures. 2nd edition. Philadelphia: Lippincott, William and Williams; 2001. p. 858–66.
[6] Soignet SL, Maslak P, Wang ZG, et al. Complete remission after treatment of acute promyelocytic leukemia with arsenic trioxide. N Engl J Med 1998;339:1341–8.
[7] Kosnett M. Arsenic. In: Brent J, Wallace KL, Burkhart KK, et al, editors. Critical care toxicology. Philadelphia: Mosby; 2005. p. 799–815.

[8] Rahman MM, Chowdhury UK, Mukherjee SC, et al. Chronic arsenic toxicity in Bangladesh and West Bengal, India: a review and commentary. Clin Toxicol 2001;39: 683–700.
[9] Subramanian KS, Kosnett MJ. Human exposures to arsenic from consumption of well water in West Bengal, India. Int J Occup Environ Health 1998;4:217–30.
[10] Gorby MS. Arsenic poisoning. West J Med 1988;149:308–15.
[11] Lai VW, Sun Y, Ting E, et al. Arsenic speciation in human urine: are we all the same? Toxicol Appl Pharmacol 2004;198:297–306.
[12] Le XC, Lu X, Ma M, et al. Speciation of key arsenic metabolic intermediates in human urine. Anal Chem 2000;72:5172–7.
[13] Pinto SS, Nelson KW. Arsenic toxicology and industrial exposure. Annu Rev Pharmacol Toxicol 1976;16:95–100.
[14] Winski SL, Carter DE. Arsenate toxicity in human erythrocytes: characterization of morphologic changes and determination of the mechanism of damage. J Toxicol Environ Health A 1998;53:345–55.
[15] Carter DE, Aposhian HV, Gandolfi AJ. The metabolism of inorganic arsenic oxides, gallium arsenide, and arsine: a toxicochemical review. Toxicol Appl Pharmacol 2003;193: 309–34.
[16] Mahieu P, Buchet JP, Roels HA, et al. The metabolism of arsenic in humans acutely intoxicated by As2O3. Its significance for the duration of BAL therapy. Clin Toxicol 1981;18:1067–75.
[17] Radabaugh TR, Aposhian HV. Enzymatic reduction of arsenic compounds in mammalian systems: reduction of arsenate to arsenite by human liver arsenate reductase. Chem Res Toxicol 2000;13:26–30.
[18] Abernathy CO, Liu YP, Longfellow D, et al. Arsenic: health effects, mechanisms of actions, and research issues. Environ Health Perspect 1999;107:593–7.
[19] Webb J. Arsenicals. Volume 3. New York: Academic Press; 1966.
[20] Gillies AJ, Taylor AJ. Acute arsenical poisoning in Dunedin. N Z Med J 1979;89:379–81.
[21] Levin-Scherz JK, Patrick JD, Weber FH, et al. Acute arsenic ingestion. Ann Emerg Med 1987;16:702–4.
[22] Mathieu D, Mathieu-Nolf M, Germain-Alonso M, et al. Massive arsenic poisoning effect of hemodialysis and dimercaprol on arsenic kinetics. Intensive Care Med 1992;18:47–50.
[23] Kyle RA, Pease GL. Hematologic aspects of arsenic intoxication. N Engl J Med 1965;273: 18–23.
[24] Fennell JS, Stacy WK. Electrocardiographic changes in acute arsenic poisoning. Ir J Med Sci 1981;150:338–9.
[25] Glazener FS, Ellis JG, Johnson PK. Electrocardiographic findings with arsenic poisoning. Calif Med 1968;109:158–62.
[26] Murphy MJ, Lyon LW, Taylor JW. Subacute arsenic neuropathy: clinical and electrophysiological observations. J Neurol Neurosurg Psychiatry 1981;44:896–900.
[27] Oh SJ. Electrophysiological profile in arsenic neuropathy. J Neurol Neurosurg Psychiatry 1991;54:1103–5.
[28] Donofrio PD, Wilbourn AJ, Albers JW, et al. Acute arsenic intoxication presenting as Guillain-Barre-like syndrome. Muscle Nerve 1987;10:114–20.
[29] Jenkins RB. Inorganic arsenic and the nervous system. Brain 1966;89:479–98.
[30] Hall AH. Chronic arsenic poisoning. Toxicol Lett 2002;128:69–72.
[31] Shannon RL, Strayer DS. Arsenic-induced skin toxicity. Hum Toxicol 1989;8:99–104.
[32] Tay CH. Cutaneous manifestations of arsenic poisoning due to certain Chinese herbal medicine. Australas J Dermatol 1974;15:121–31.
[33] Mees RA. Een verschijnsel bij polyneuritis arsenicosa. Ned Tijdschr Verloskd Gynaecol 1919;1:391–6.
[34] Tseng CH. Blackfoot disease and arsenic: a never-ending story. J Environ Sci Health C Environ Carcinog Ecotoxicol Rev 2005;23:55–74.

[35] Jackson R, Grainge JW. Arsenic and cancer. Can Med Assoc J 1975;113:396–401.
[36] Lugo G, Cassady G, Palmisano P. Acute maternal arsenic intoxication with neonatal death. Am J Dis Child 1969;117:328–30.
[37] Vantroyen B, Heilier JF, Meulemans A, et al. Survival after a lethal dose of arsenic trioxide. Clin Toxicol 2004;42:889–95.
[38] Shamberger RJ. Validity of hair mineral testing. Biol Trace Elem Res 2002;87:1–28.
[39] Aposhian HV. DMSA and DMPS—water soluble antidotes for heavy metal poisoning. Annu Rev Pharmacol Toxicol 1983;23:193–215.
[40] Aposhian HV, Carter DE, Hoover TD, et al. DMSA, DMPS, and DMPA—as arsenic antidotes. Fundam Appl Toxicol 1984;4:S58–70.
[41] Aposhian HV, Maiorino RM, Gonzalez-Ramirez D, et al. Mobilization of heavy metals by newer, therapeutically useful chelating agents. Toxicology 1995;97:23–38.
[42] Stocken L, Thompson R. British Anti-Lewisite: 2, Dithiol compounds as antidotes for arsenic. Biochem J 1946;40:535–48.
[43] Vaziri ND, Upham T, Barton CH. Hemodialysis clearance of arsenic. Clin Toxicol 1980; 17:451–6.
[44] Klimecki WT, Carter DE. Arsine toxicity: chemical and mechanistic implications. J Toxicol Environ Health 1995;46:399–409.
[45] Romeo L, Apostoli P, Kovacic M, et al. Acute arsine intoxication as a consequence of metal burnishing operations. Am J Ind Med 1997;32:211–6.
[46] Fowler BA, Weissberg JB. Arsine poisoning. N Engl J Med 1974;291:1171–4.
[47] Amante L, Magistretti M, Pernis B. The action of arsine on reduced glutathione. Med Lav 1961;52:11–3.
[48] Ayala-Fierro F, Barber DS, Rael LT, et al. In vitro tissue specificity for arsine and arsenite toxicity in the rat. Toxicol Sci 1999;52:122–9.
[49] Blair PC, Thompson MB, Bechtold M, et al. Evidence for oxidative damage to red blood cells in mice induced by arsine gas. Toxicology 1990;63:25–34.
[50] Kensler C, Abels J, Rhoads C. Arsine poisoning, mode of action and treatment. J Pharmacol Exp Ther 1946;5:99–108.
[51] Pernis B, Magistretti M. A study of the mechanism of acute hemolytic anemia from arsine. Med Lav 1960;51:37–41.
[52] Peterson DP, Bhattacharyya MH. Hematological responses to arsine exposure: quantitation of exposure response in mice. Fundam Appl Toxicol 1985;5:499–505.
[53] Rael LT, Ayala-Fierro F, Carter DE. The effects of sulfur, thiol, and thiol inhibitor compounds on arsine-induced toxicity in the human erythrocyte membrane. Toxicol Sci 2000;55:468–77.
[54] Winski SL, Barber DS, Rael LT, et al. Sequence of toxic events in arsine-induced hemolysis in vitro: implications for the mechanism of toxicity in human erythrocytes. Fundam Appl Toxicol 1997;38:123–8.
[55] Coles GA, Davies HJ, Daley D, et al. Acute intravascular haemolysis and renal failure due to arsine poisoning. Postgrad Med J 1969;45:170–2.
[56] Ayala-Fierro F, Carter DE. LLC-PK1 cells as a model for renal toxicity caused by arsine exposure. J Toxicol Environ Health A 2000;60:67–79.
[57] Uldall PR, Khan HA, Ennis JE, et al. Renal damage from industrial arisine poisoning. Br J Ind Med 1970;27:372–7.
[58] Macaulay DB, Stanley DA. Arsine poisoning. Br J Ind Med 1956;13:217–21.
[59] McKinstry WJ, Hickes JM. Emergency; arsine poisoning. AMA Arch Ind Health 1957; 16:32–41.
[60] Pino P, Walter T, Oyarzun MJ, et al. Rapid drop in infant blood lead levels during the transition to unleaded gasoline use in Santiago, Chile. Arch Environ Health 2004;59: 182–7.
[61] Hesdorffer CS, Milne FJ, Terblanche J, et al. Arsine gas poisoning: the importance of exchange transfusions in severe cases. Br J Ind Med 1986;43:353–5.

[62] Hocken AG, Bradshaw G. Arsine poisoning. Br J Ind Med 1970;27:56–60.
[63] Teitelbaum DT, Kier LC. Arsine poisoning. Report of five cases in the petroleum industry and a discussion of the indications for exchange transfusion and hemodialysis. Arch Environ Health 1969;19:133–43.
[64] Apostoli P, Alessio L, Romeo L, et al. Metabolism of arsenic after acute occupational arsine intoxication. J Toxicol Environ Health 1997;52:331–42.
[65] Rusyniak DE, Furbee RB, Kirk MS. Thallium and arsenic poisoning in a small midwest town. Ann Emerg Med 2002;39:307–11.
[66] Lynch GR, Lond MB. The toxicology of thallium. Lancet Dec 1930;20:1340–4.
[67] Bank WJ, Pleasure DE, Suzuki K, et al. Thallium Poisoning. Arch Neurol 1972;26:456–64.
[68] Reed D, Crawley J, Faro SN, et al. Thallotoxicosis. JAMA 1963;183:516–22.
[69] Desenclos JC, Wilder MH, Coppenger GW, et al. Thallium poisoning: an outbreak in Florida 1988. South Med J 1992;85:1203–6.
[70] Insley BM, Grufferman S, Ayliffe HE. Thallium poisoning in cocaine abusers. Am J Emerg Med 1986;4:545–8.
[71] Malbrain ML, Lambrecht GL, Zandijk E, et al. Treatment of severe thallium intoxication. Clin Toxicol 1997;35:97–100.
[72] Meggs WJ, Hoffman RS, Shih RD, et al. Thallium poisoning from maliciously contaminated food. Clin Toxicol 1994;32:723–30.
[73] Moore D, House I, Dixon A. Thallium poisoning: diagnosis may be elusive but alopecia is the clue. BMJ 1993;306:1527–9.
[74] Questel F, Dugarin J, Dally S. Thallium-contaminated heroin. Ann Intern Med 1996;124:616.
[75] Waters CB, Hawkins EC, Knapp DW. Acute thallium toxicosis in a dog. J Am Vet Med Assoc 1992;201:883–5.
[76] Lund A. Distribution of thallium in the organism and its elimination. Acta Pharmacol Toxicol (Copenh) 1956;12:251–9.
[77] Douglas KT, Bunni MA, Baindur SR. Thallium in biochemistry. Int J Biochem 1990; 22:429–38.
[78] Gehring PJ, Hammond PB. The interrelationship between thallium and potassium in animals. J Pharmacol Exp Ther 1967;155:187–201.
[79] Mulkey JP, Oehme FW. A review of thallium toxicity. Vet Hum Toxicol 1993;35:445–53.
[80] Melnick RL, Monti LG, Motzkin SM. Uncoupling of mitochondrial oxidative phosphorylation by thallium. Biochem Biophys Res Commun 1976;69:68–73.
[81] Cavanagh JB, Fuller NH, Johnson HRM. The effects of thallium salts, with particular reference to the nervous system changes: a report of three cases. Q J Med 1974;170: 293–319.
[82] Tromme I, Van Neste D, Dobbelaere F, et al. Skin signs in the diagnosis of thallium poisoning. Br J Dermatol 1998;138:321–5.
[83] Moeschlin S. Thallium poisoning. Clin Toxicol 1980;17:133–46.
[84] Feldman J, Levisohn DR. Acute alopecia: clue to thallium toxicity. Pediatr Dermatol 1993; 10:29–31.
[85] Heyl T, Barlow RJ. Thallium poisoning: a dermatological perspective. Br J Dermatol 1989; 121:787–91.
[86] McMillan TM, Jacobson RR, Gross M. Neuropsychology of thallium poisoning. J Neurol Neurosurg Psychiatry 1997;63:247–50.
[87] Davis LE, Standefer JC, Kornfeld M, et al. Acute thallium poisoning: toxicological and morphological studies of the nervous system. Ann Neurol 1980;10:38–44.
[88] Koblenzer PJ, Weiner LB. Alopecia secondary to thallium intoxication. Arch Dermatol 1969;99:777.
[89] Metter D, Vock R. [Structure of the hair in thallium poisoning]. Z Rechtsmed 1984;91: 201–14.
[90] Cavanagh JB. The 'dying back' process. A common denominator in many naturally occurring and toxic neuropathies. Arch Pathol Lab Med 1979;103:659–64.

[91] Cavanagh JB. What have we learnt from Graham Frederick Young? Reflections on the mechanism of thallium neurotoxicity. Neuropathol Appl Neurobiol 1991;17:3–9.
[92] Thompson DF, Callen ED. Soluble or insoluble Prussian blue for radiocesium and thallium poisoning? Ann Pharmacother 2004;38:1509–14.
[93] Hoffman RS. Thallium toxicity and the role of Prussian blue in therapy. Toxicol Rev 2003; 22:29–40.
[94] Barroso-Moguel R, Villeda-Hernandez J, Mendez-Armenta M, et al. Combined D-penicillamine and Prussian blue as antidotal treatment against thallotoxicosis in rats: evaluation of cerebellar lesions. Toxicology 1994;89:15–24.
[95] Heydlauf H. Ferric-cyanoferrate (II):An effective antidote in thallium poisoning. Eur J Pharmacol 1969;6:340–4.
[96] Kamerbeek HH, Rauws AG, Ham MT, et al. Prussian blue in therapy of thallotoxicosis: an experimental and clinical investigation. Acta Med Scand 1971;189:321–4.
[97] Manninen V, Malkonen M, Skulskii IA. Elimination of thallium in rats as influenced by Prussian blue and sodium chloride. Acta Pharmacol Toxicol (Copenh) 1976;39: 256–61.
[98] Meggs WJ, Cahill-Morasco R, Shih RD, et al. Effects of Prussian blue and N-acetylcysteine on thallium toxicity in mice. Clin Toxicol 1997;35:163–6.
[99] Rauws AG. Thallium pharmacokinetics and its modification by Prussian blue. Naunyn Schmiedebergs Arch Pharmacol 1974;284:295–306.
[100] Rios C, Monroy-Noyola A. D-penicillamine and Prussian blue as antidotes against thallium intoxication in rats. Toxicology 1992;74:69–76.
[101] Rusyniak DE, Kao LW, Nanagas KA, et al. Dimercaptosuccinic acid and Prussian blue in the treatment of acute thallium poisoning in rats. Clin Toxicol 2003;41:137–42.
[102] Pearce J. Studies of any toxicological effects of Prussian blue compounds in mammals–a review. Food Chem Toxicol 1994;32:577–82.
[103] Lund A. The effect various substances on the excretion and the toxicity of thallium in the rat. Acta Pharmacol Toxicol (Copenh) 1956;12:260–8.
[104] Van der Stock J, Schepper J. The effect of Prussian blue and sodium-ethylenediaminetetraacetic acid on the faecal and urinary elimination of thallium by the dog. Res Vet Sci 1978;25: 337–42.
[105] Hoffman RS, Stringer JA, Feinberg RS, et al. Comparative efficacy of thallium adsorption by activated charcoal, Prussian blue, and sodium polystyrene sulfonate. Clin Toxicol 1999; 37:833–7.
[106] Lehmann PA, Favari L. Parameters for the adsorption of thallium ions by activated charcoal and Prussian blue. Clin Toxicol 1984;22:331–9.
[107] Goldwater LJ. Hat industry. In: Goldwater LJ, editor. Mercury: a history of quicksilver. Baltimore (MD): York Press; 1955.
[108] Graeme KA, Pollack CV. Heavy metal toxicity, Part I: arsenic and mercury. J Emerg Med 1998;16:45–56.
[109] Richer J, DeWoskin R. ATSDR. Toxicological profile for MERCURY. In: US Department of Health and Human Services. Atlanta (GA): Agency for Toxic Substances and Disease Registry; 1999. p. 3–676.
[110] O'Shea JG. "Two minutes with Venus, two years with mercury": mercury as an antisyphilitic chemotherapeutic agent. J R Soc Med 1990;83:392–5.
[111] Lide Dr., editor. CRC handbook of chemistry and physics. 86th edition. Boca Raton (FL): CRC Press; 2005.
[112] Rishler JF, Amler SN. Mercury exposure: evaluation and intervention in the inappropriate use of chelation agents in the diagnosis and treatment of putative mercury poisoning. Neurotoxicology 2005;26:691–9.
[113] Boyd AS, Seger D, Vannucci S, et al. Mercury exposure and cutaneous disease. J Am Acad Dermatol 2000;43:81–90.
[114] Gutierrez F, Lucio L. Elemental mercury embolism to the lung. N Engl J Med 2000;342:1791.

[115] Bredfeldt JE, Moeller DD. Systemic mercury intoxication following rupture of a Miller-Abbott tube. Am J Gastroenterol 1978;69:478–80.
[116] McKinney PE. Elemental mercury in the appendix: an unusual complication of a Mexican-American folk remedy. Clin Toxicol 1999;37:103–7.
[117] Nanagas KA, O'Connor AD, Potts ME, et al. Conservative management of elemental mercury sequestration in the appendix. Clin Toxicol 2003;41:A52.
[118] Chang LW, Verity MA. Mercury neurotoxicity: effects and mechanisms. In: Chang LW, Dyer RS, editors. Handbook of neurotoxicology. New York: Marcel Dekker; 1995. p. 31–59.
[119] Rowens B, Guerrero-Betancourt D, Gottlieb CA, et al. Respiratory failure and death following acute inhalation of mercury vapor: a clinical and histologic perspective. Chest 1991;99:185–90.
[120] Aguado S, de Quiros IF, Marin R, et al. Acute mercury vapour intoxication: report of six cases. Nephrol Dial Transplant 1989;4:133–6.
[121] Clarkson TW, Magos L, Myers GJ. The toxicology of mercury: current exposures and clinical manifestations. N Engl J Med 2003;349:1731–7.
[122] Dally A. The rise and fall of pink disease. Soc Hist Med 1997;10:291–304.
[123] Sedano HO. Mercury poisoning and acrodynia. Oral Surg Oral Med Oral Pathol Oral Radiol Endod 1998;85:349.
[124] Harrop-Griffiths H. Adult pink disease. BMJ 1970;1:298.
[125] Beuter A, de Geoffroy A. Can tremor be used to measure the effect of chronic mercury exposure in human subjects? Neurotoxicology 1996;17:213–27.
[126] Netterstrom B, Guldager B, Heeboll J. Acute mercury intoxication examined with coordination ability and tremor. Neurotoxicol Teratol 1996;18:505–9.
[127] Henningsson C, Hoffmann S, McGonigle L. Acute mercury poisoning (acrodynia) mimicking pheochromocytoma in an adolescent. J Pediatr 1993;122:252–3.
[128] Torres AD, Ashok NR, Hardiek ML. Mercury intoxication and arterial hypertension: report of two patients and review of the literature. Pediatrics 2000;105:E34.
[129] Wossmann W, Kohl M, Gruning G, et al. Mercury intoxication presenting with hypertension and tachycardia. Arch Dis Child 1999;80:556–7.
[130] Archbold GP, McGuckin RM, Campbell NA. Dimercaptosuccinic acid loading test for assessing mercury burden in healthy individuals. Ann Clin Biochem 2004;41: 233–6.
[131] Kosnett MJ. Unanswered questions in metal chelation. Clin Toxicol 1992;30:529–47.
[132] Martin-Gil J, Martin-Gil FJ, Delibes-de-Castro G, et al. The first known use of vermillion. Experientia 1995;51:759–61.
[133] DeBont B, Lauwerys R, Govaerts H, et al. Yellow mercuric oxide ointment and mercury intoxication. Eur J Pediatr 1986;145:217–8.
[134] Dargan P, Giles L, Wallace C, et al. Case report: severe mercuric sulphate poisoning treated with 2,3-dimercaptopropane-1-sulphonate and haemodiafiltration. Crit Care 2003;7:R1–6.
[135] Endo T, Nakaya S, Kimura R, et al. Gastrointestinal absorption of inorganic mercuric compounds in vivo and in situ. Toxicol Appl Pharmacol 1984;74:223–9.
[136] Fardal O, Johannessen AC, Morken T. Gingivo-mucosal and cutaneous reactions to amalgam fillings. J Clin Periodontol 2005;32:430–3.
[137] Laeijendecker R, Dekker SK, Burger PM, et al. Oral lichen planus and allergy to dental amalgam restorations. Arch Dermatol 2004;140:1434–8.
[138] Schrallhammer-Benkler K, Ring J, Przybilla B, et al. Acute mercury intoxication with lichenoid drug eruption followed by mercury contact allergy and development of antinuclear antibodies. Acta Derm Venereol 1992;72(4):294–6.
[139] Zalups RK, Ahmad S. Homocysteine and the renal epithelial transport and toxicity of inorganic mercury: role of basolateral transporter organic anion transporter 1. J Am Soc Nephrol 2004;15:2023–31.

[140] Newton JA, House IM, Volans GN, et al. Plasma mercury during prolonged acute renal failure after mercuric chloride ingestion. Hum Toxicol 1983;2:535–7.
[141] Aymaz S, Gross O, Krakamp B, et al. Membranous nephropathy from exposure to mercury in the fluorescent-tube-recycling industry. Nephrol Dial Transplant 2001;16:2253–5.
[142] Harada M. Minamata disease: methylmercury poisoning in Japan caused by environmental pollution. Crit Rev Toxicol 1995;25:1–24.
[143] Tsuchiya K. The discovery of the causal agent of Minamata disease. Am J Ind Med 1992; 21:275–80.
[144] Kondo K. Congenital Minamata disease: warnings from Japan's experience. J Child Neurol 2000;15:458–64.
[145] Tedeschi LG. The Minamata disease. Am J Forensic Med Pathol 1982;3:335–8.
[146] Eto K. Minamata disease. Neuropathology 2000;20(Suppl):S14–9.
[147] Bakir F, Damluji SF, Amin-Zaki L, et al. Methylmercury poisoning in Iraq. Science 1973; 181:230–41.
[148] Aberg B, Ekman L, Falk R, et al. Metabolism of methyl mercury (203Hg) compounds in man. Arch Environ Health 1969;19:478–84.
[149] Berlin M, Carlson J, Norseth T. Dose-dependence of methylmercury metabolism. A study of distribution: biotransformation and excretion in the squirrel monkey. Arch Environ Health 1975;30:307–13.
[150] Eto K, Tokunaga H, Nagashima K, et al. An autopsy case of Minamata disease (methylmercury poisoning): pathological viewpoints of peripheral nerves. Toxicol Pathol 2002; 30:714–22.
[151] Harada M. Congenital Minamata disease: intrauterine methylmercury poisoning. Teratology 1978;18:285–8.
[152] Bakir F, Rustam H, Tikriti S, et al. Clinical and epidemiological aspects of methylmercury poisoning. Postgrad Med J 1980;56:1–10.
[153] Hviid A, Stellfeld M, Wohlfahrt J, et al. Association between thimerosal-containing vaccine and autism. JAMA 2003;290:1763–6.
[154] Baselt RC. Disposition of toxic drugs and chemicals in man. 6th edition. Foster City (CA): Biomedical Publications; 2002.
[155] Nierenberg DW, Nordgren RE, Chang MB, et al. Delayed cerebellar disease and death after accidental exposure to dimethylmercury. N Engl J Med 1998;338:1672–6.
[156] Clarkson TW, Magos L, Cox C, et al. Tests of efficacy of antidotes for removal of methylmercury in human poisoning during the Iraq outbreak. J Pharmacol Exp Ther 1981;218: 74–83.
[157] Aaseth J, Frieheim EA. Treatment of methyl mercury poisoning in mice with 2,3-dimercaptosuccinic acid and other complexing thiols. Acta Pharmacol Toxicol (Copenh) 1978;42:248–52.
[158] Zimmer LJ, Carter DE. The efficacy of 2,3-dimercaptopropanol and D-penicillamine on methyl mercury induced neurological signs and weight loss. Life Sci 1978;23:1025–34.
[159] Hernberg S. Lead poisoning in a historical perspective. Am J Ind Med 2000;38:244–54.
[160] Gilfillan SC. Lead Poisoning and the fall of Rome. J Gnathol 1965;85:53–60.
[161] Lockitch G. Perspectives on lead toxicity. Clin Biochem 1993;26:371–81.
[162] Staudinger KC, Roth VS. Occupational lead poisoning. Am Fam Physician 1998;57: 719–26, 731–2.
[163] Mowad E, Haddad I, Gemmel DJ. Management of lead poisoning from ingested fishing sinkers. Arch Pediatr Adolesc Med 1998;152:485–8.
[164] Haley VB, Talbot TO. Seasonality and trend in blood lead levels of New York state children. BMC Pediatr 2004;4:8.
[165] Canfield RL, Henderson CR Jr, Cory-Slechta DA, et al. Intellectual impairment in children with blood lead concentrations below 10 microg per deciliter. N Engl J Med 2003;348: 1517–26.

[166] Lidsky TI, Schneider JS. Lead neurotoxicity in children: basic mechanisms and clinical correlates. Brain 2003;126:5–19.
[167] Goldstein GW. Neurologic concepts of lead poisoning in children. Pediatr Ann 1992; 21:384–8.
[168] Johnston MV, Goldstein GW. Selective vulnerability of the developing brain to lead. Curr Opin Neurol 1998;11:689–93.
[169] Slobozhanina EI, Kozlova NM, Lukyanenko LM, et al. Lead-induced changes in human erythrocytes and lymphocytes. J Appl Toxicol 2005;25:109–14.
[170] Besunder JB, Super DM, Anderson RL. Comparison of dimercaptosuccinic acid and calcium disodium ethylenediaminetetraacetic acid versus dimercaptopropanol and ethylenediaminetetraacetic acid in children with lead poisoning. J Pediatr 1997;130:966–71.
[171] American Academy of Pediatrics issues treatment guidelines for lead exposure in children. Am Fam Physician 1995;52:1022–3.
[172] Dietrich KN, Ware JH, Salganik M, et al. Effect of chelation therapy on the neuropsychological and behavioral development of lead-exposed children after school entry. Pediatrics 2004;114:19–26.
[173] Rogan WJ, Dietrich KN, Ware JH, et al. The effect of chelation therapy with succimer on neuropsychological development in children exposed to lead. N Engl J Med 2001;344: 1421–6.
[174] Hu H, Aro A, Payton M, et al. The relationship of bone and blood lead to hypertension. The normative aging study. JAMA 1996;275:1171–6.
[175] Maslinski PG, Loeb JA. Pica-associated cerebral edema in an adult. J Neurol Sci 2004; 225:149–51.
[176] Barats MS, Gonick HC, Rothenberg S, et al. Severe lead-induced peripheral neuropathy in a dialysis patient. Am J Kidney Dis 2000;35:963–8.
[177] Rabinowitz MB. Toxicokinetics of bone lead. Environ Health Perspect 1991;91:33–7.
[178] Magos L. Lead poisoning from retained lead projectiles: a critical review of case reports. Hum Exp Toxicol 1994;13:735–42.
[179] Hu H, Pepper L, Goldman R. Effect of repeated occupational exposure to lead, cessation of exposure, and chelation on levels of lead in bone. Am J Ind Med 1991;20:723–35.